Developmental problems of upper limb

Dr. Ip Wing-yuk
Queen Mary Hospital
The University of Hong Kong

Developmental disorder

Lesions pertaining to development

- Congenital lesions that are not obvious at birth
  - bony lesions
  - CNS lesions
  - vascular lesions
- Non-congenital lesions that are complicated by growth
  - post-traumatic conditions
  - inflammatory joint disease

Topics for today

- Bony lesions: Madelung's deformity, multiple exostosis, pseudoarthrosis of upper limb, developmental radial head dislocation, radio-ulnar synostosis, fibrous dysplasia
- Soft tissue lesion: vascular malformation
- CNS lesion: cerebral palsy
- Inflammatory joint disease: Juvenile inflammatory arthritis

Medelung's deformity

- Growth disturbance of the palmar and ulnar portion of the distal radius physis, may involve whole radius
- Scaphoid facet and radial styloid normal
- Excessive radial and palmar angulation of distal radius
- Abnormal palmar ligament tethering the lunate to radius, proximal to physis (vicker's ligament)
- Dominant inheritance of Leri-Weill dyschondrosteosis, mutation of SHOX gene
- Repeated loading with physeal injury may mimic the condition

Clinical features

- Distal ulnar is dorsally prominent
- Distal radius appears to have dorsal concavity in lateral view
- Shorter forearm
- Usually minimal functional impairment so most do not need treatment
- Pain caused DRUJ instability may limit function

Indication for surgical intervention

- Cosmesis: physiolysis with release of abnormal ligament
- Before skeletal maturity

Indication for surgical intervention

Pain: Options:

- dome osteotomy+ ligament resection
- radial closing osteotomy+ ulnar shortening
- radial opening osteotomy
- radial osteotomy+ Sauve-Kapandji procedure or other DRUJ procedures

Hereditary multiple exostosis

- Disorder of enchondroal plate, osteochondromata grow from physis of long bone
- Autosomal dominant,mutated gene for formation of EXT protein, which is an enzyme for synthesis of heparin sulphate
- Longitudinal and angulatory growth abnormality with forearm deformity

Types

- 1. main osteochondroma in distal ulna: short ulna and bowed radius
- 2. main osteochondroma in distal ulna, short ulna and bowed radius, radial head dislocation

2a. Osteochondroma on proximal radial metaphysis

2b. No proximal radial osteochondroma

- 3. main osteochondroma is in distal radius and the radius is relatively short

Indication for surgical treatment

- Lumps causing local pain, nerve compression
- Impairing forearm rotation
- Visible deformity and discrepancy of growth between radius and ulna
- Radial head dislocation
- Malignant transformation 1-5%

Types of procedures

- Simple excision
- Distal radial hemi-epiphyseal stapling
- Sauve-Kapandji procedure
- Radial head excision
- Differential forearm lengthening- osteotomy, fixation, ulnar lengthening, angular correction, radial head reduction

5 Steps to manage complicated forearm osteochondromata

- Resect osteochondroma
- Correct ulnar bowing to increase interosseous space
- Correct distal radial tilt
- Correct length discrepancy between bones
- Reduce radial head subluxation/dislocation

Radio-ulnar synostosis

- Congenital: fibrous, bony, associated with radial head dislocation
- Post-traumatic: in proximal forearm, mid-forearm, distal forearm
- Sequlae of Monteggia fracture, closed head injury with heterotopic ossification
- Loss of rotation and progressive radial head subluxation

Indication for surgery

- Not able to compensate by other mobile joint in upper limb with functional problems
- Various methods to separate synostosis usually fail
- Osteotomy for better position

Fibrous dysplasia

- Abnormal bone growth where medullary cavity is replaced by fibrous tissue
- Abnormal bone growth or swelling of bone
- Most are monostotic, asymptomatic and identified incidentally
- Most can be treated with observation
- Symptoms: pain, irregular bone growth, bone deformity, one fracture
- No known cure

Pseudoarthrosis of radius and ulna

- Associated with neurofibromatosis
- A segment, usually ulna is replaced by fibrous tissue
- Autosomal dominant
- Progressive forearm deformity,

  forearm short as one bone bears

  all the load, causing radius bowing, radial head dislocation
- Diminished rotation
- Pain, instability, weakness

Surgical treatment

- Achieve bone union, stabilize DRUJ, UCJ, allow continued bone growth
- Creation of 1 bone forearm
- External distraction technique combined with compression at pseudarthrosis site
- Resection of pseudathrosis + vascularized fibular grafting more reliable

CNS conditions

- Cerebral palsy: a group of permanent movement disorders that appears in childhood, caused by abnormal development or damage to the parts of the brain that control movement, balance and posture
- Post-cerebral vascular accident eg. AVM
- Brain damage after birth

Organic Brain Damage

Pyramidal system

Extra Pyramidal system

Loss of voluntary control of some muscles

Loss of inhibitory control of reflex arc

Abnormal pattern
In coordination
Slow speed

Spasticity
Vicious cycle of muscle imbalance
(Shortening & weakening of tonic muscles,
Lengthening & weakening of phasic muscles

Static & dynamic deformity
of bone & soft tissues, which is specific for the brain damage

Hand control is by cotico-spinal pathway

Classification based on motor function

- Spastic type
- Non-spastic type

  - dyskinetic
  - ataxic
  - hypotonic
  - mixed

Typical deformity in spastic type

- **Shoulder : adduction, internal rotation**
- **Elbow : flexion**
- **Forearm : pronation**
- **Wrist : palmar flexion, ulnar deviation**
- **Fingers : flexion/swan neck deformity**
- **Thumb : thumb in palm deformity**

The proximal joints are for positioning of the functional part, i.e. the hand

The deformity seems typical, but brain damage is very individual

Typical deformity

Spasticity

- Acts like a brake on the system & reduces speed of movement, increases energy consumption
- Inhibits voluntary control
- Shortened muscle works in ascending part of length/tension curve – lead to weakness
- Lengthened muscle works in descending part of length/tension curve – lead to weakness

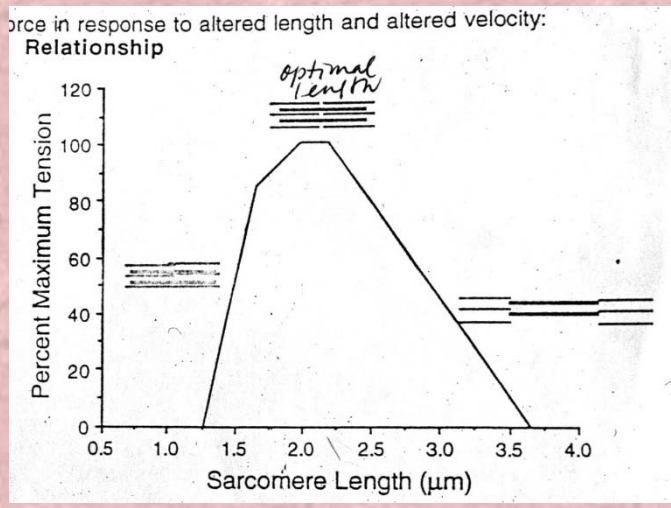

Treatment of spasticity

- Muscle control/relaxation techniques
- Splints to reposition part, modify muscle strength
- Electrical stimulation of antagonistic muscles
- Neurosurgical procedures: fasiculotomy of peripheral nerves
- Pharmacologic agents: baclofen
- Botulinum-A toxin injections
- *MUSCULOSKELETAL OPERATIONS*

Surgical indications

- Voluntary use of hand during activities, with good potential for functional improvement

- Deformity interferes with function- upper limb, gait hygiene, discomfort
- (cosmesis)

Pre-op Evaluation

- Each patient has different degree of CNS lesion and treatment should be individualized
- Multiple examination: motor, sensory, intelligence, social (family support, parental stress, home environment, peer group)
- Pattern of movement disorder: spastic, dyskinetic, ataxic or mixed
- Classification: Manual ability Classification system; House Functional Classification; Zancolli's classification of active finger and wrist extension; Modified House classification of thumb-in-palm deformity

Pre-op Motor Evaluation of UL

- Observation of activities
- Whole upper limb examination rather than individual muscle
- Pattern of hand usage
- Speed of movement
- How much is the imbalance of agonist & antagonist?
- How good is the voluntary control, any mirror movement
- Potential muscle for transfer: spasticity, power, voluntary control
- EMG study: phasic activities, recruitment pattern
- Fixed deformities

Evaluate grasp & release with wrist flexed, wrist neutral, wrist extended



Zancolli classification of Hand & wrist

GR	Zancolli, JHS 1983
I	Finger extension with wrist in neutral or less than 20º of flexion
IIA	Active wrist extensors present. Finger extension only with wrist in more than 20º of flexion
IIB	No active wrist extensors present. Finger extension only with wrist in more than 20º of flexion
III	Finger extension not possible even with maximal wrist flexion



Botulinum A toxin (Botox) injection

Facilitates surgical decision for patient & surgeon

Before & after Botox injection to intrincics

Timing of surgery

- Consider better cerebral plasticity at younger age, less neglect
- Need to understand & comply with rehabilitation programme
- Staged procedures are frequently required
- Clear evaluation of functional use of hand is possible (age 6-12)
- Adult can still be benefited if there is all along some functional use

Surgical goals

- Improve quality of life: function, cosmesis, comfort, hygiene, gait
- Improve upper limb function: range of movement, strength & endurance
- Poor helping hand to better helping hand in patient with 1 hand more severely involved

Musculo-skeletal surgery

- Only deal with spasticity & its sequalae
- No way to deal with dystonia & sensory deficit
- Restore muscle balance around joints
- Achieve best sacromere length
- Achieve stable joint in functional position
- Control pain by decrease spasticity, better hygiene by better posture, improve gait with better bilateral upper limb positioning

Surgical intervention

Shoulder	External rotated & abducted for ADL
Elbow	Extended
Forearm	Neutral rotation
Wrist	Neutral flexion
Digits	Extended out of palm

Surgical planning

- **Address the spastic agonist**

  or augment the antagonist to achieve balance at a joint

- **Proximal to distal, extrinsic to intrinsic**

  proximal surgery may alter distal pattern of spasticity:

Correct of wrist flexion deformity may affect digital positioning (further digital flexor tightness)

Swan neck deformity after long flexors lengthening

- **Do not use Classification patterns to make surgical decisions**
- **Avoid reverse deformity**

Surgical options

Procedures	Shoulder Adduction	Elbow flexion	Forearm pronation	Wrist flexion/UD	Thumb in palm	Finger deformity
Release		Bicipital aponeurosis	PT release PQ release	Flexor/ Pronator fascial release	1st web Z plasty adductor release 1st DI release	Intrinsic release at origin/insertion
Lengthening	PM lengthening Subscapularis lengthening	Biceps lengthening Brachialis lengthening	PT lengthening	FCU lengthening FCR lengthening	FPL lengthening	FDS, FDP lengthening
Tendon transfer	LD transfer to poster-lateral humerus		PT re-routing FCU → ECRB	BR→ECRL/B ECU → ECRL/B FCU → ECRL/B FCR → ECRL/B PT → ECRL/B	PL→APL PL→EPL PL→EPB FCR→APL BR→EPB BR→EPL EPL re-routing ACC APL → EPB	FCU → EPC BR → EDC 1st band re-routing FDS tenodesis
Bone/joint Stabilization			Rotational osteotomy	Wrist fusion with PRC PRC	MCPJ fusion MCP capsulodesis Thumb IPJ fusion	DIPJ fusion Volar plate Capsulodesis PIPJ fusion

Shoulder

- Target : improve space of movement of upper limb, improve positioning of hand, improve hygiene, better gait
- Key muscle imbalance: spastic Pectoralis major
- Operative procedure: Fractional lengthening of PM, Z-plasty of Subscapularis

Fractional lengthening of Pectoralis Major to gain passive abduction & external rotation

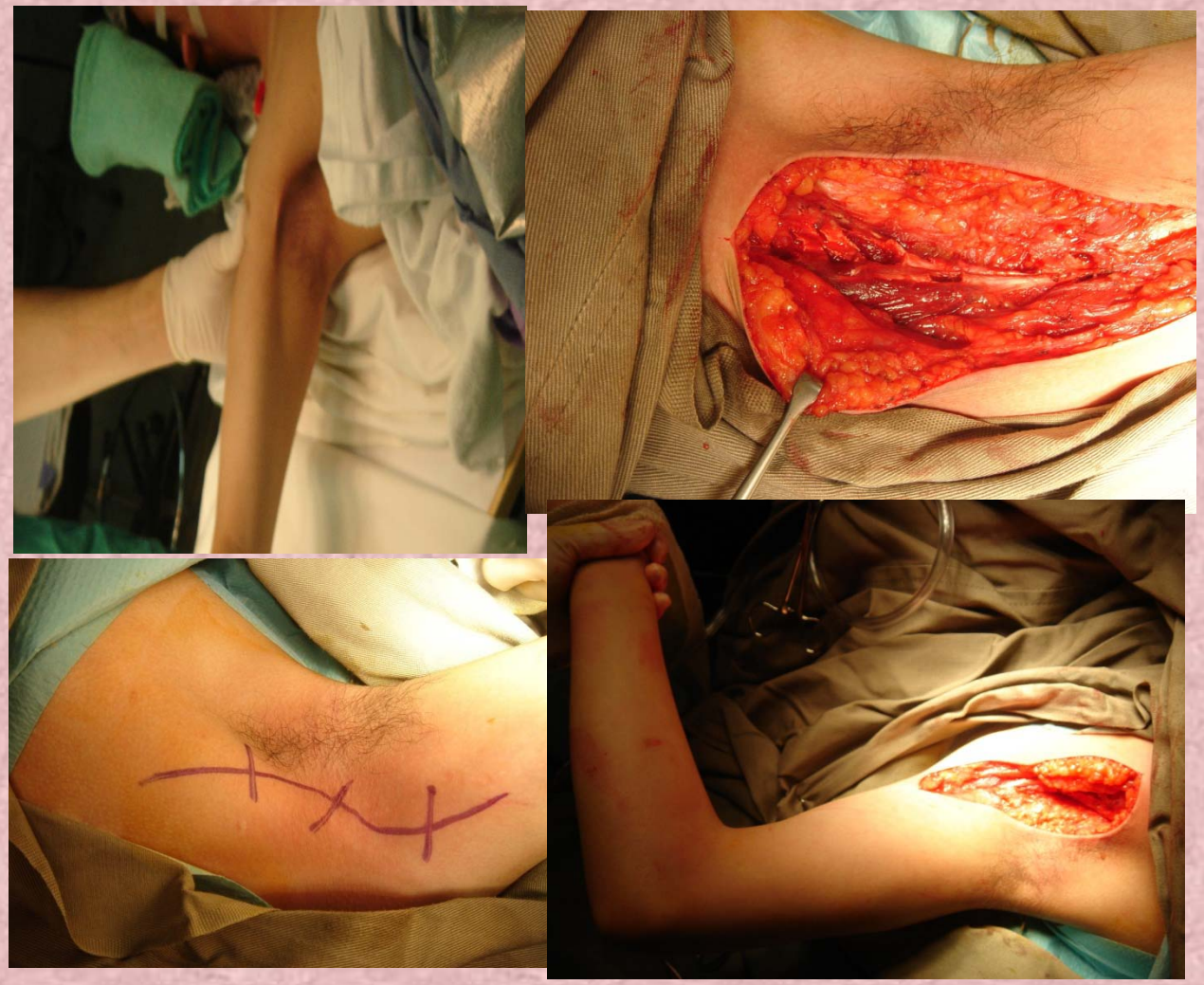

Elbow

- Target: improve positioning of forearm & hand (extension), improve cosmesis by ↓ flexor tone
- Typical deformity : elbow flexion
- Key muscle imbalance : spastic biceps & brachialis Vs. normal/weak triceps
- Operative procedures : Biceps fractional /z lengthening, Brachialis lengthening, release of bicipital aponeurosis, fascial release of commom flexor origin
- Manske 2001: 49˚improvement in flexion posture angle, active extension 43˚to 27˚, use of arm ↑from 12% to 44%

Workhorse procedure: Bicipital aponeurotic release, flexor aponeurotic release till elbow can be extended passively

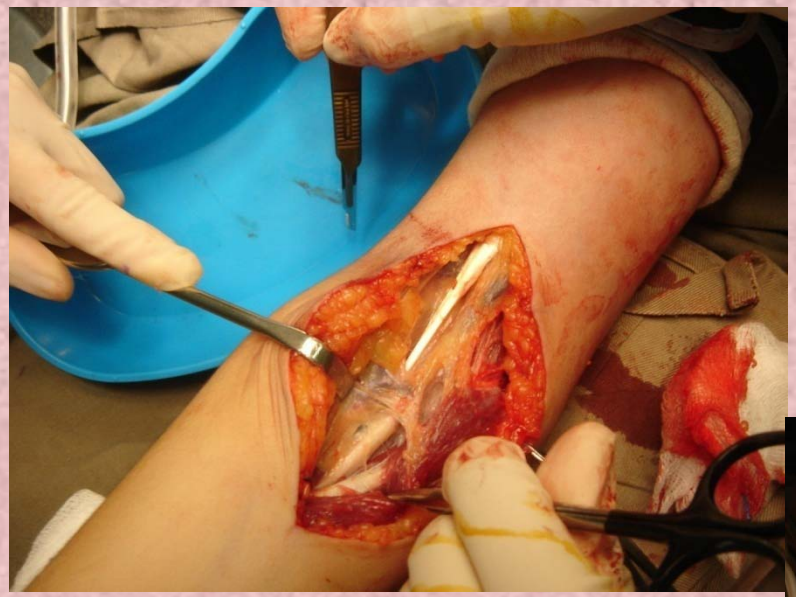

Forearm

- Target : some supination in at least 1 forearm, to visualize thumb during ADL, prevent radial head dislocation which results in loss of rotation & pain
- Operative procedures :
  - PT lengthening to decrease pronator tone
  - PT release when supination short of neutral
  - PQ release for patient with tight passive supination
  - PT re-routing for patient with no active supination
  - FCU → ECRB transfer has a supination component
- Bunata et. Al.2006: PT re-routing ↑65˚supination
- Cheema et.al. 2006: FCU to ECRB more effective to produce supination than PT re-routing or BR re-routing

Workhorse procedure: Forearm rotation

- Fractional Pronator teres lengthening at musculo-tendinous junction
- Partial relaease of PQ at origin
- FCU transfer to ECRB, which deals with wrist extension & has a supination action

Wrist

- Target : active wrist extension to functional position, improve cosmesis
- Typical deformity : flexion/ulnar deviation
  - Static : fixed flexion contracture of > 45°
  - Dynamic : active extension to 45 ° less than neutral
  - Functional : full active range, but as spastic flexors fire, wrist pulled into flexion
  - Key muscle imbalance : weak wrist extensors, tight/or spastic wrist flexion ± finger flexors
  - 2 ° capsular contracture

Finger flexion deformity

Target: Hand opening with wrist neutral

improve cosmesis

Operative procedures : fractional lengthening of FDS/FDP up to full extension with wrist in neutral

FCU, BR → EDC

Workhorse procedure for wrist

For patient with active finger extensor
FCU transfer to ECRB
Tension transfer at 0-5° flexion

Fractional lengthening of long flexors till digits can be extended passively

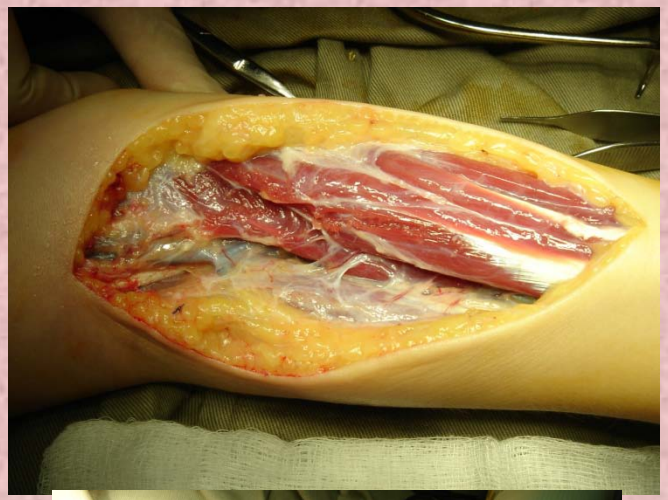

Fingers

For patients with no active finger extensor

- FCU/BR transfer to EDC

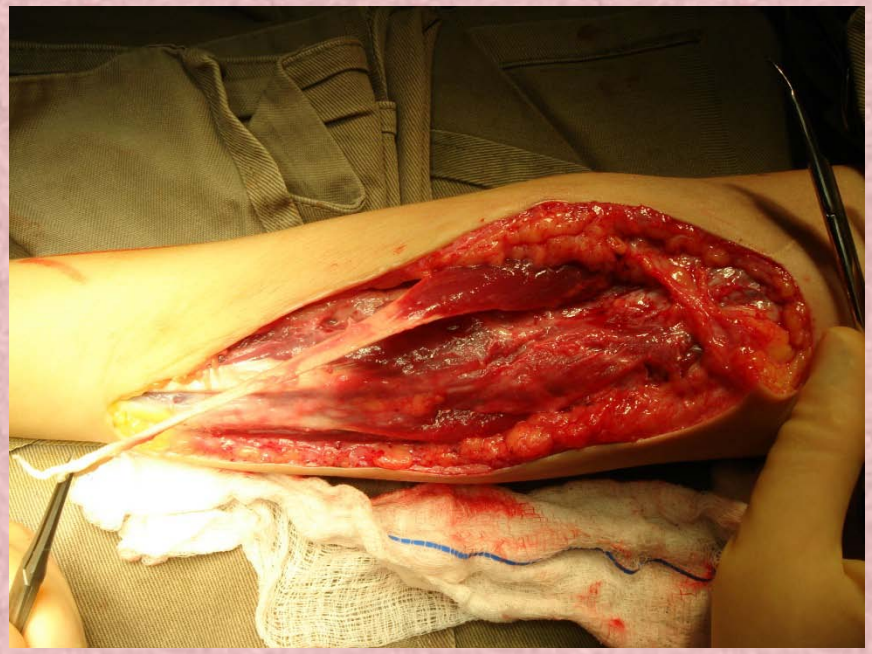

Pre-op Vs Post-op

Pre-op

Post-op

Wrist fusion for motionless hand to improve hygiene & cosmesis, make a stable wrist for stabilizing objects

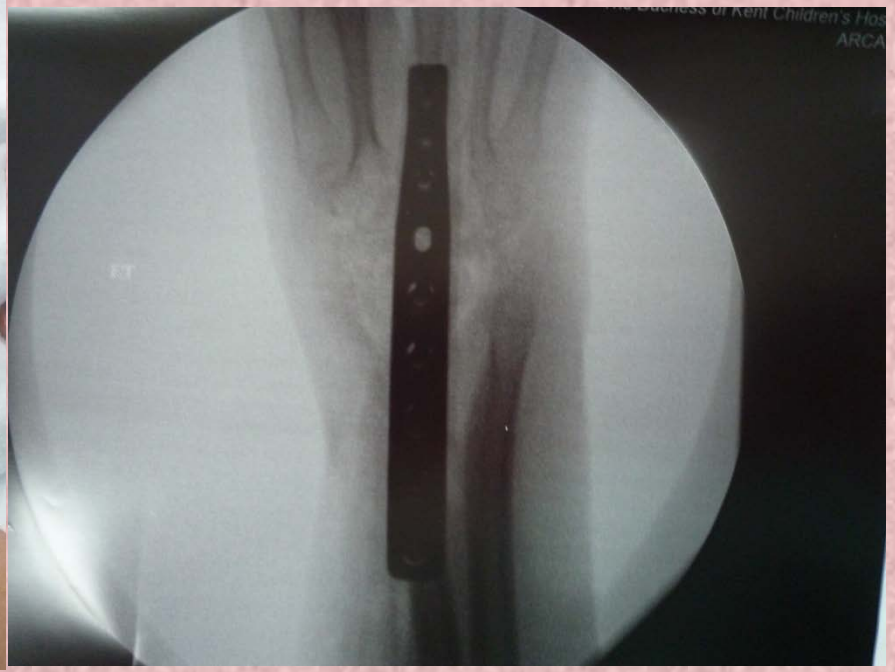

Swan Neck deformity

Target :

- Stable PIPJ
- Faster & smooth hand closing
- Improve cosmesis

Key muscle imbalance : intrinsic spasticity

- intrinsic tightness unmasked after long flexor release

Many operative procedures

- Intrinsic release at origin or insertion
- Lateral band re-routing
- FDS tenodesis
- Central slip tenotomy
- Spinal oblique retinacular ligament reconstruction
- PIPJ fusion
- PIPJ volar plate capsulodesis
- DIPJ fusion

Partial intrinsic release at origin improve in resting posture
Lateral band to volar plate to achieve balance

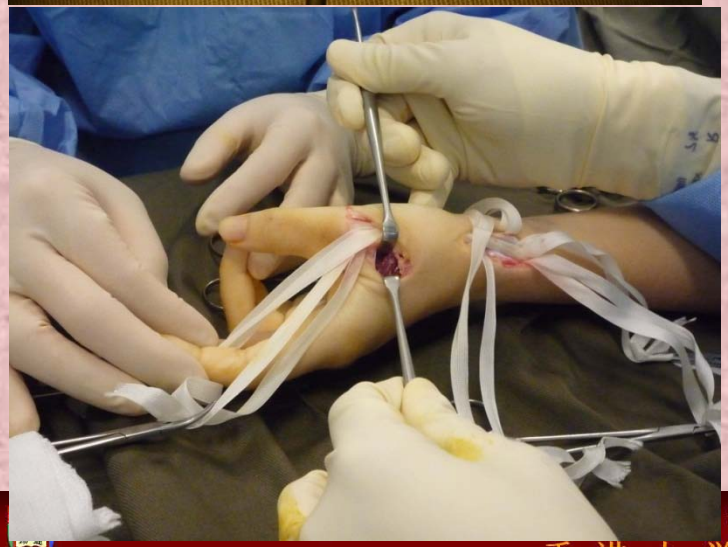

Thumb in palm deformity

Target-Improve thumb positioning during fisting

-Improve thumb abduction during hand opening

Operative procedures :

- ↑1st web space by Z plasty
- Identify the muscle imbalance

decrease the tone of spastic muscle, augment the weakened muscle to achieve balance

- Achieve good resting posture by tenodesis effect, or bony realignmemt with arthrodesis

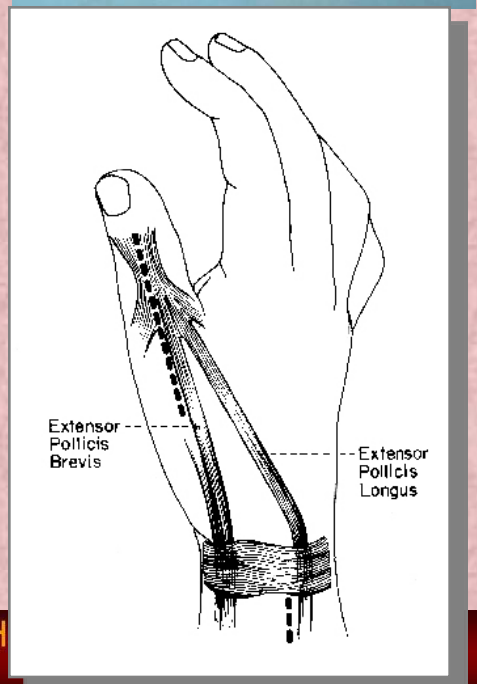

Intrinsic release: FPB release , Adductor pollicis release at origin

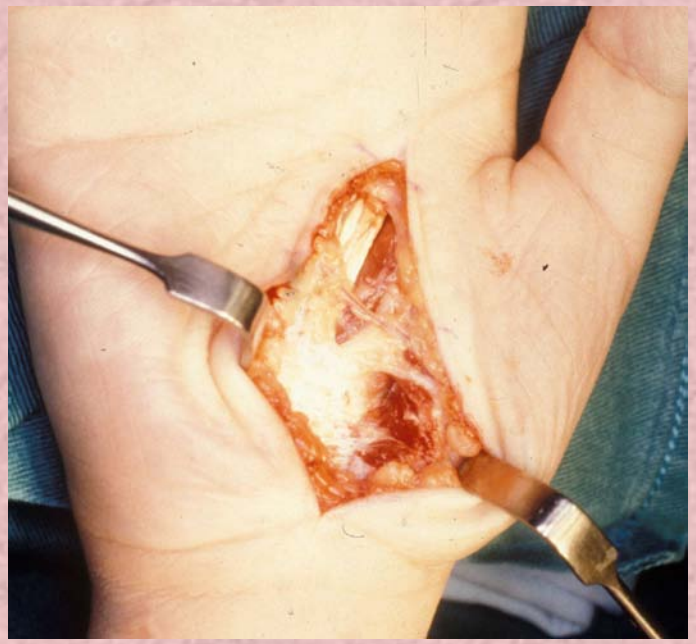

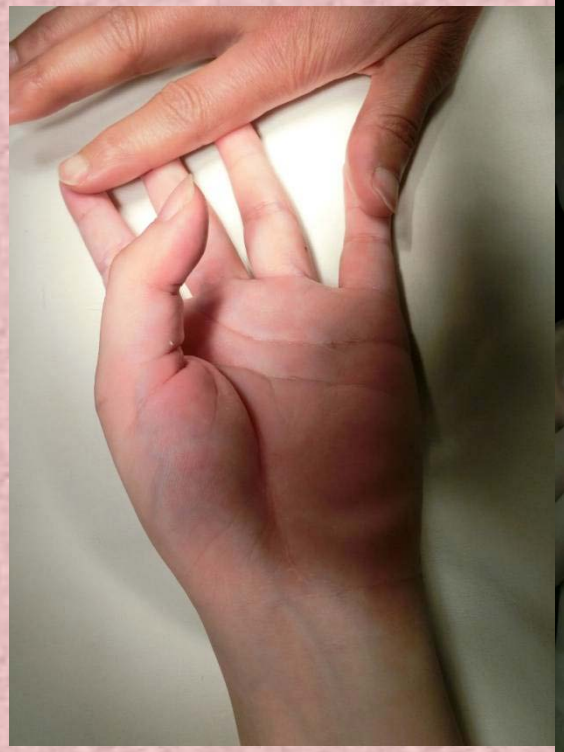

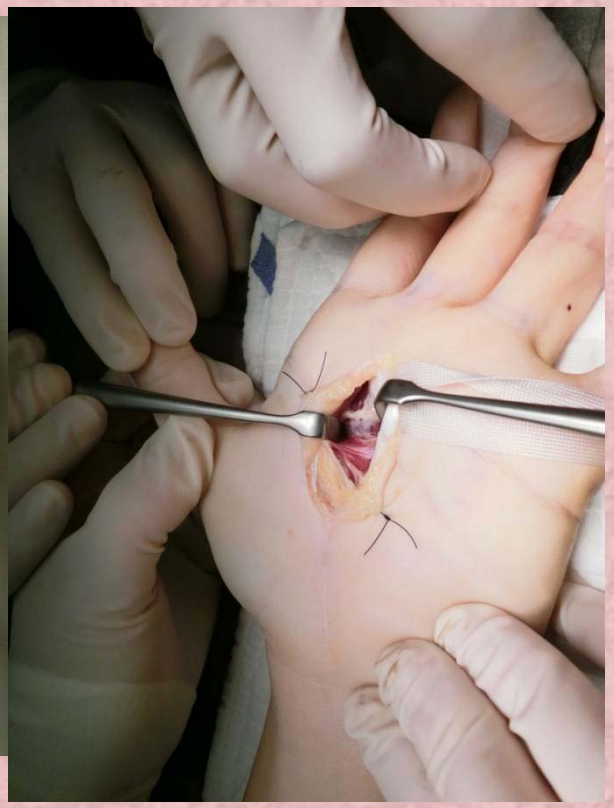

APL tenodesis to FCR & ECRL as sling of the thumb for good resting posture

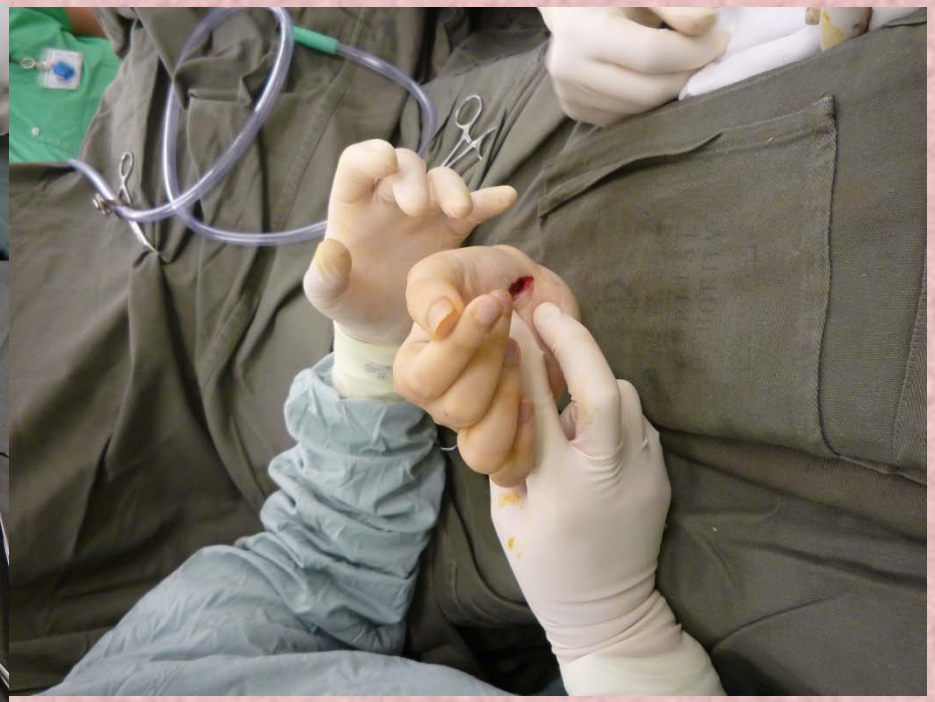

Post-op Rehabilitation

- Cortical control of motor unit is specific
- Tendon transfer changes the whole system
- The motor system must re-learn motor program to fully utilize the release/transfer

- Splint program according to surgical details
- Protect transferred tendon
- Prevent adhesion or rupture.

Vascular Tumours

- Complex classification
- Malignant ones extremely rare
- Benign ones might be locally aggressive and difficult to treat
- Gradual increase in size after birth

Non-neoplastic vascular malformations

- Slow flow

  capillary, venous, lymphatic
- High flow

  arterial, AV fistulae, AV malformations
- Complex combine

Problems in the upper limb

- Increase size of limb
- Functional impairment due to progressive in size, or progressive tissue ischaemia
- Signs of congestive heart failure
- Palliative Vs curative surgery

  - Embolization with wide excision +/- flap coverage, or amputation may be required

Inflammatory Arthritis affecting the growth of musculo-skeletal system

- Juvenile Idiopathic Arthritis(JIA) –used most by paediatric rheumatologist
- Malfunctioning of immune system, unknown cause
- Disease pathology similar to adult counterpart
- Involve 1 or many joints, with fever, rash, inflammation of internal organs
- Oligoarticular: < 5 joints or polyarticular

International League of Association for Rheumatology Classification of JIA

- Systemic-onset
- Persistent oligoarthritis
- RF-ve polyarthritis
- RF+ve polyarthritis
- Psoriatic
- Enthesitis-related
- Undifferentiated

Treatment

- Multi-disciplinary approach
- Control symptoms, prevent joint damage, maintain function
- Mainstay is medical: NSAIDs, DMARDs
- Orthropaedic treatment :

- solitary joint arthritis when disease is under control, synovectomy to slow down the joint damage process
- Reconstruction of deformity like adult RA patients

Special consideration for operation in growing skeleton

- Synovectomy or tenosynovectomy to reduce synovial damage should be done earlier before joint erosion
- Joint stabilization should be done after skeletal maturity
- Prosthesis arthroplasty should be considered at a later age

Earlier synovectomy to slow down cartilage and bony damage by synovitis

Tendon transfer procedures for extensor similar to adult RA
Try to preserve DRUJ, rather than excision arthroplasty

Keep auto tissue with excision arthroplasty of MCPJ rather than using prosthesis arthroplasty

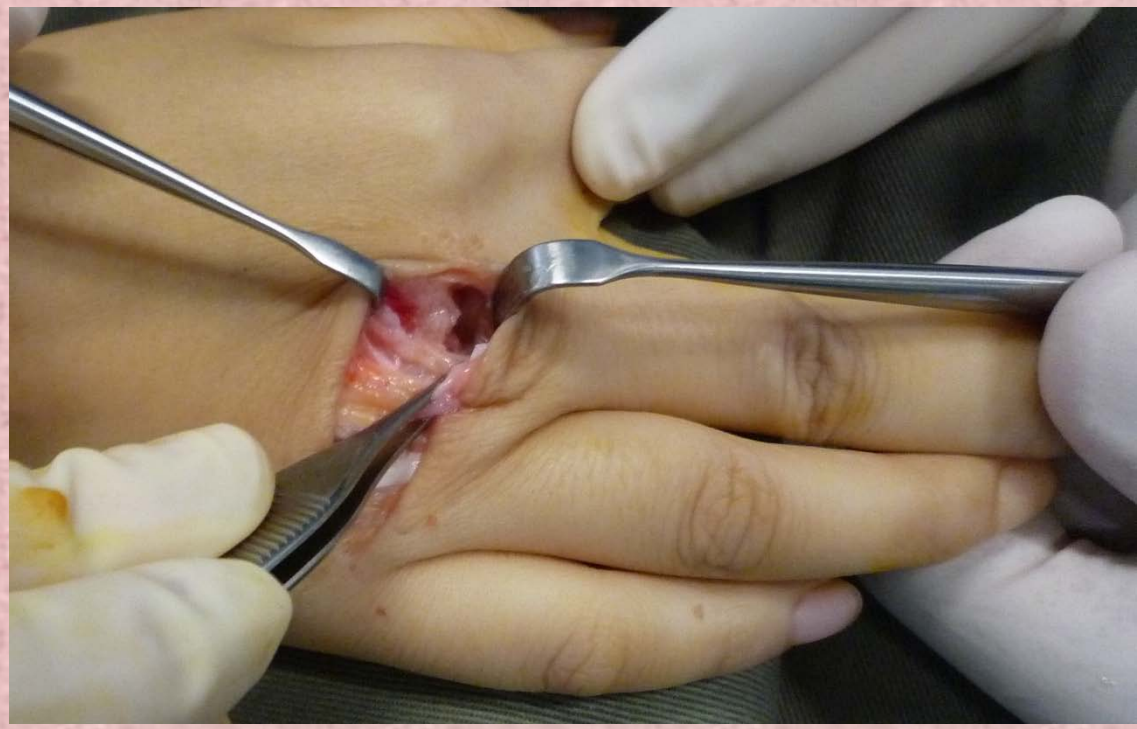

Thank you very much for your attention

wyip@hku.hk